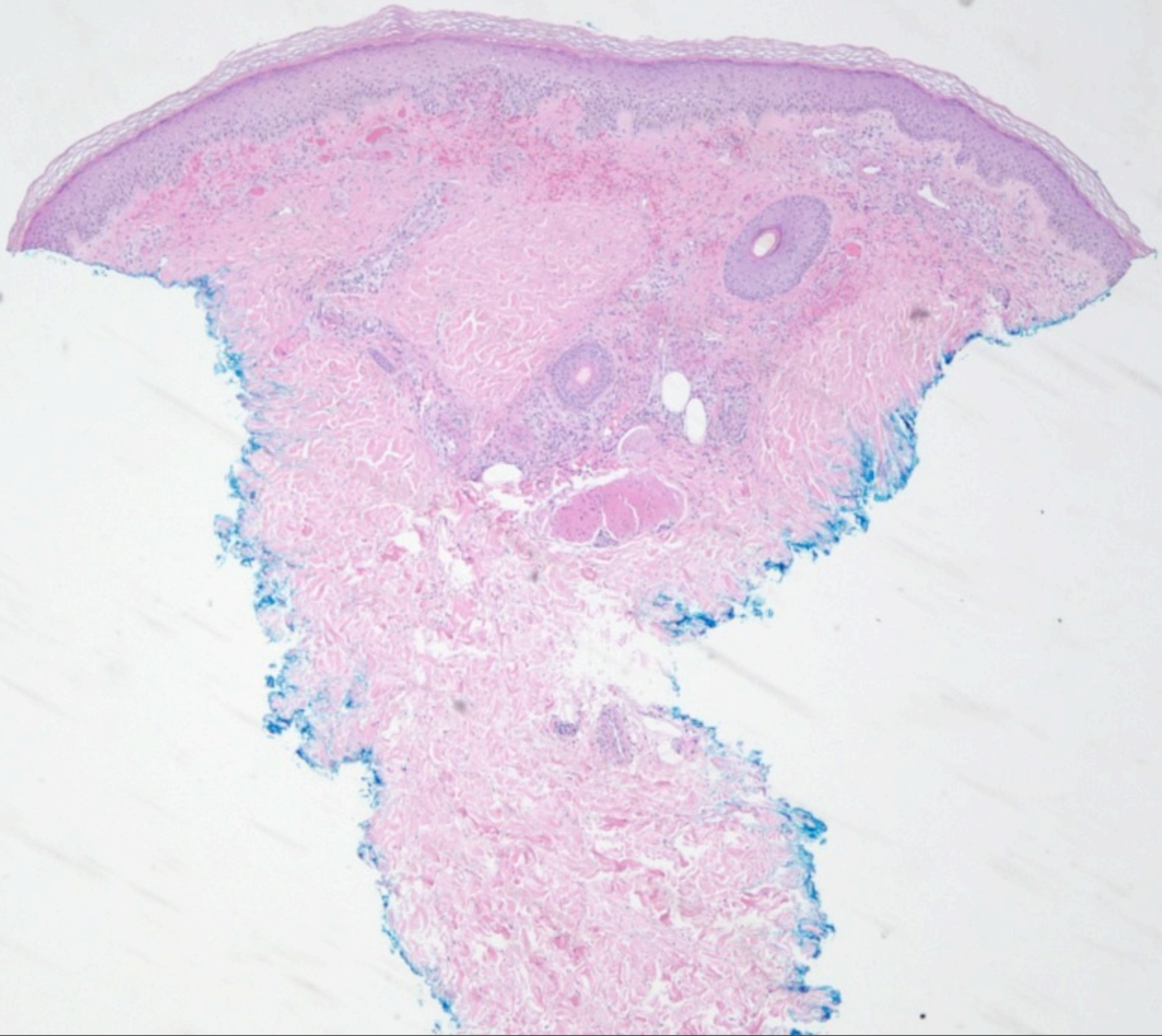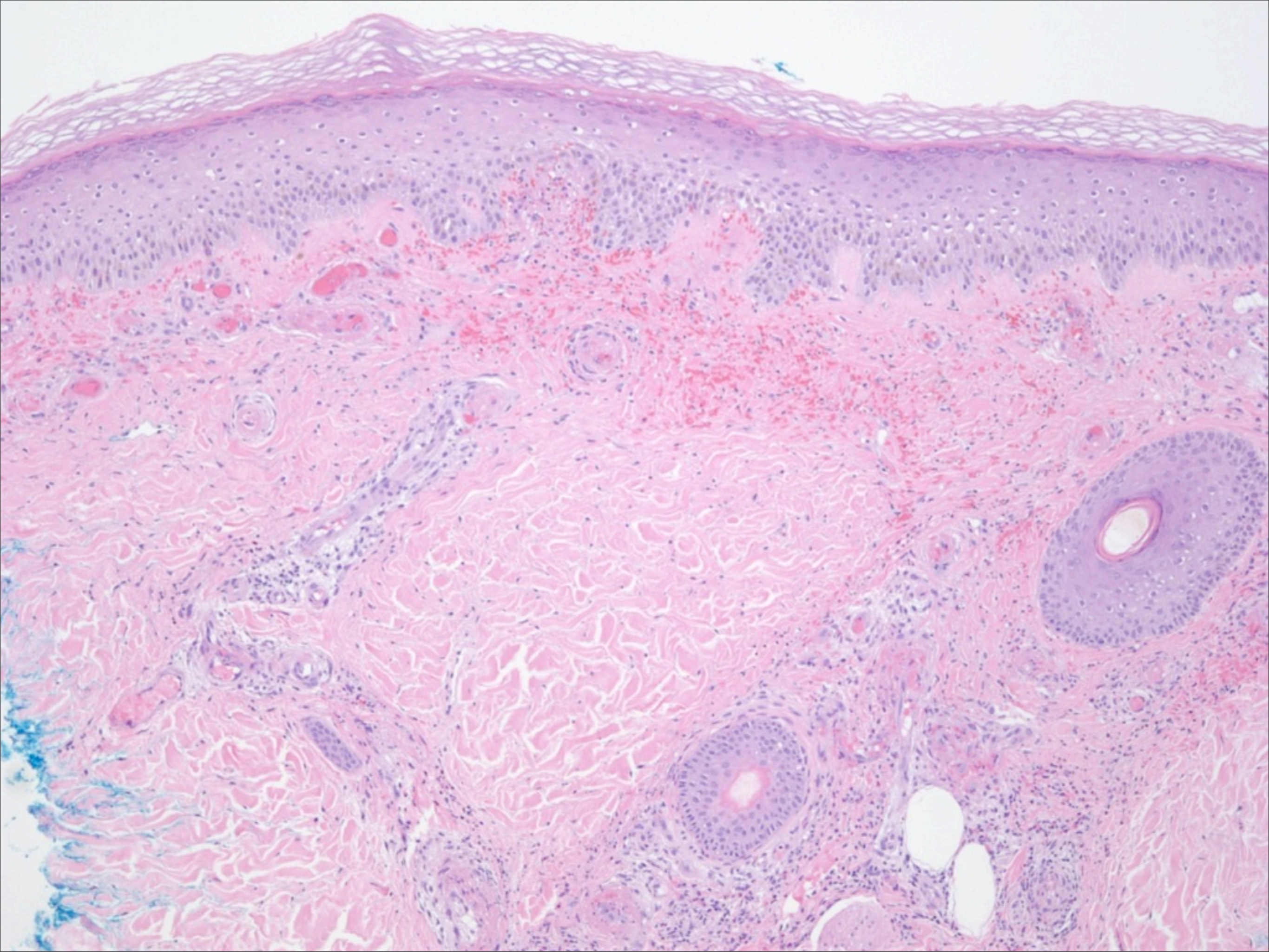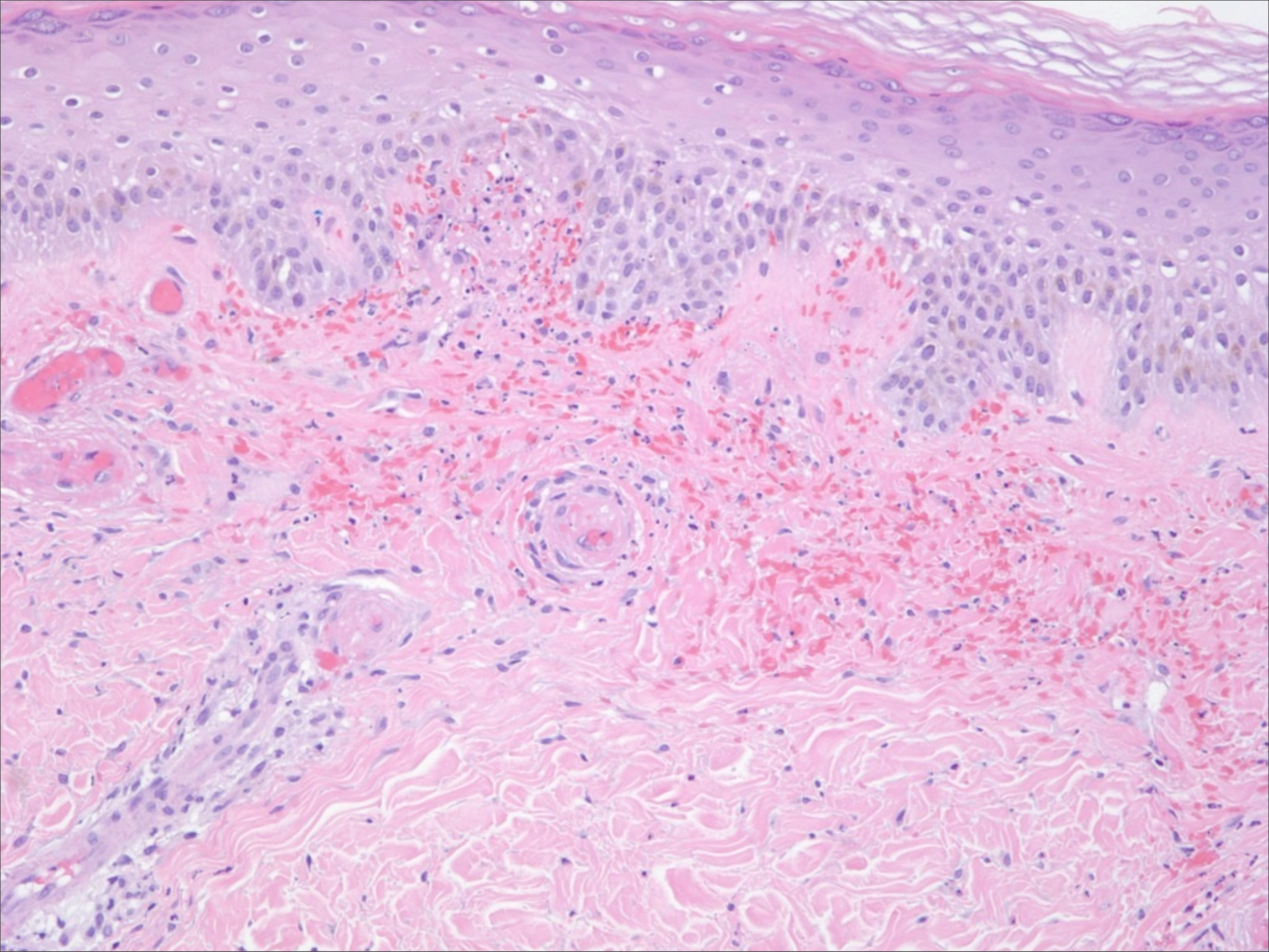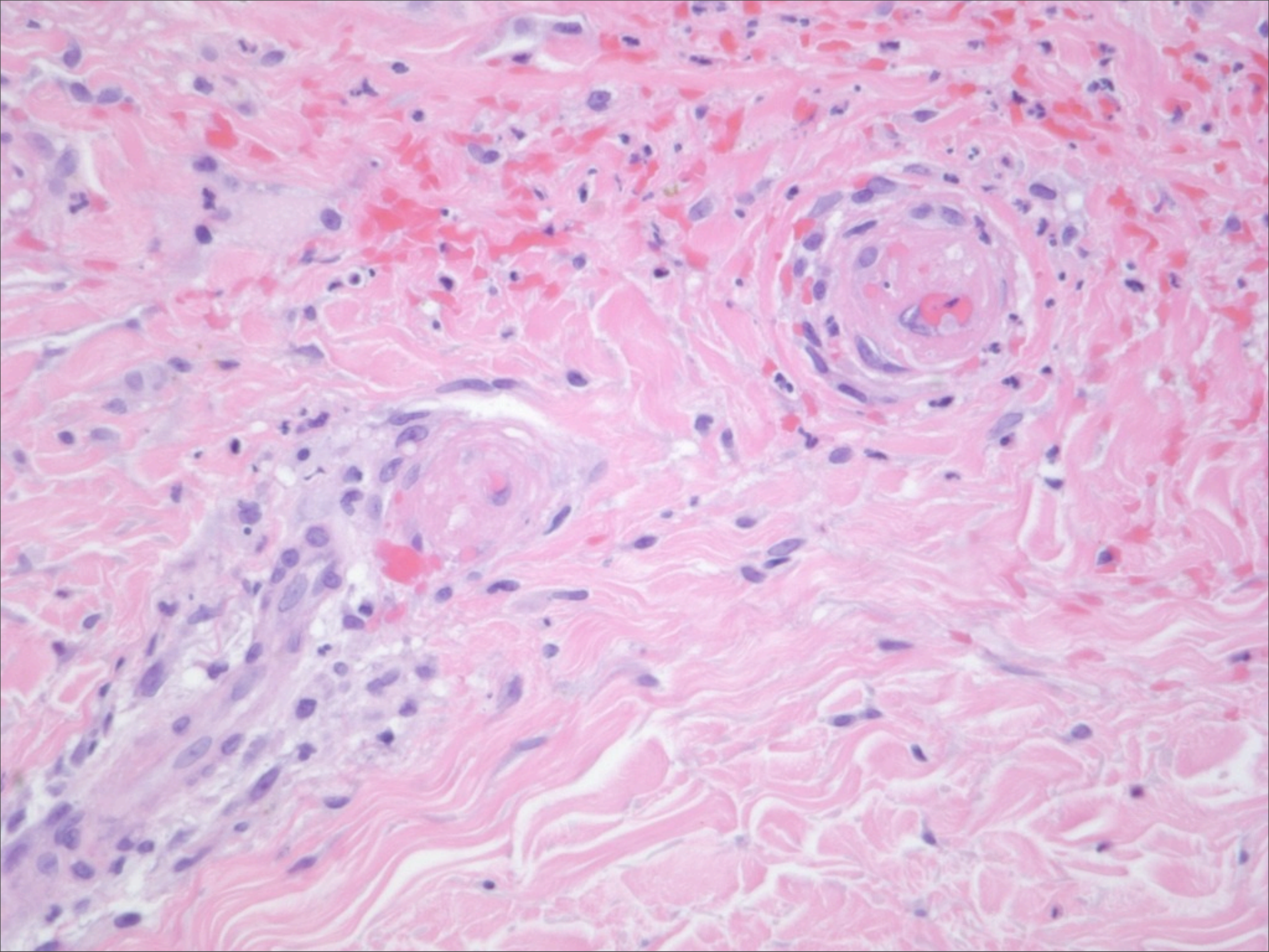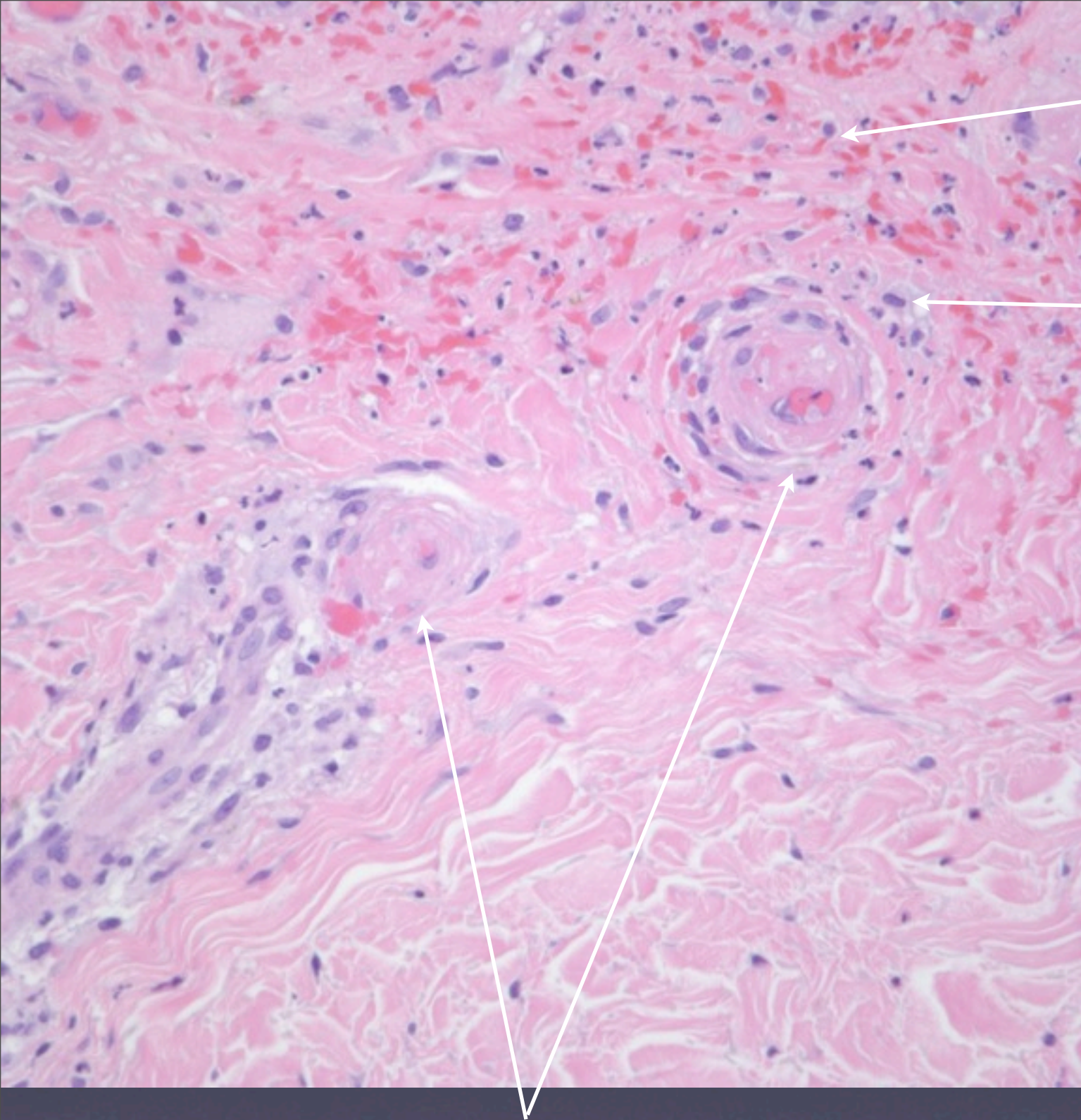


Leukocytoclastic Vasculitis



Extravasated rbc

Nuclear Dust

Must have Fibrinoid Necrosis